

Artículo de investigación

The use of planimetric analysis in studying the healing of burn wounds in animals

Применение планиметрического анализа при изучении заживления ожоговых ран у ЖИВОТНЫХ

Recibido: 20 de julio del 2019

Aceptado: 29 de agosto del 2019

Written by:

S.V. Chernigova³⁵

ORCID ID: 0000-0003-1131-7938

https://elibrary.ru/author_items.asp?authorid=623297**N.V. Zubkova**³⁶

ORCID ID: 0000-0001-9281-5335

Yu.V. Chernigov³⁷

ORCID ID: 0000-0001-6338-5823

https://elibrary.ru/author_items.asp?authorid=472569**N.A. Pogorelova**³⁸

ORCID ID: 0000-0001-8495-3869

https://elibrary.ru/author_items.asp?authorid=778144**Abstract**

The results of these studies are the basis for using a wound dressing based on bacterial cellulose in the comprehensive pathogenetic therapy of burn wounds. The process was studied on a model of III B degree planar burn wounds of rabbits. The experimental studies of the efficiency of the Derma RM wound covering have shown that its use in local treatment of uninfected deep burns prevents complications of the process of wound healing, and reduces the wounds healing time.

Keywords: Animals, surgery, bacterial cellulose, morphometry, burn wound, thermal burn, trauma, wound dressing, regeneration, epithelialization.

Аннотация

Результаты проведенных исследований являются основанием применения раневого покрытия на основе бактериальной целлюлозы в комплексной патогенетической терапии ожоговых ран. Исследование процесса проведено на модели ожоговых плоскостных ран кроликов III Б степени. Экспериментальные исследования эффективности раневого покрытия «Derma RM» показали, что применение при местном лечении неинфицированных глубоких ожогов предупреждает осложнение раневого процесса и сокращает сроки заживления ран.

Ключевые слова: животные, хирургия, бактериальная целлюлоза, морфометрия, ожоговая рана, термический ожог, травма, раневое покрытие, регенерация, эпителизация.

Introduction

For Russia, the presence of high-tech production facilities can create conditions for technological leadership and improving its position in the global pharmaceutical markets (Privolnev, et al,

2016). A large role in domestic and foreign combustiology is played by local treatment of animals with burn wounds. The main traditional method of local treatment of burn wounds is the

³⁵ Omsk State Agrarian University named after PA Stolypin, Omsk, Russia

³⁶ Omsk State Agrarian University named after PA Stolypin, Omsk, Russia

³⁷ Omsk Agricultural Research Center, Omsk, Russia

³⁸ Omsk State Agrarian University named after PA Stolypin, Omsk, Russia

use of bandages. Currently, over 400 wound dressings have been created and patented, which act on the individual links of the wound process pathogenesis (Nazarenok, Sugorova, Glyantsev, 2002; Schmidt-Nielsen, 1987). Despite this fact, there is a high rate of burn wounds complications and of development of systemic toxic inflammatory reaction, which increases the risk of mortality (Chernigova, Chernigov, 2016a). The delayed healing process of such wounds is due to the large area, the extensive necroses, infection, excessive exudation, secondary trauma, maceration, and skin dehydration (Abayev, 2006; Paramonov, Porembsky, Jablonsky, 2000; Kanjanamosit, Muangnapoh, Phisalaphong, 2009). Today, the issue of searching for a universal dressing remains relevant; the dressing should be less traumatic to the newly formed epithelium, should have pronounced long-lasting local antibacterial action, and promote drainage of the wound exudate (Czaja, Krystynowicz, Bielecki, 2006). Such a wound dressing should remain efficient in all phases of wound healing. The solution of this problem may be promoted by studying the nanostructured bacterial cellulose with high adsorption activity, the properties of which have been insufficiently studied (Chernigova, Chernigov, 2016b; Chernigova, et al., 2018; Popov, 2013; Wang, et al., 2011).

The study was aimed at assessing the efficiency of using the Derma RM wound dressing based on bacterial cellulose for experimental animals with thermal injuries using the planimetric analysis.

Materials and methods

The study was performed within the framework of the scientific research topic AAAA-A16-116040610034-2 "Development of Surgical Tools and Methods for Improving the Quality of Life of Animals and Assessment of Productive Properties" at the Department of Diagnostics, Internal Noncontagious Diseases, Pharmacology, Surgery and Obstetrics at the Institute of Veterinary Medicine and Biotechnology of the Omsk State Agrarian University, the Laboratory of Biology with the basics of Molecular Biotechnology and Genetic Engineering of the Omsk State Agrarian University, the Laboratory of Biochemical Analysis at the Department of Animal Breeding of the Omsk Agricultural Research Center. The Derma RM wound dressing has been developed and manufactured at the Department of Food and Nutrition Biotechnology of the Agricultural Technology Department of the Omsk State Agricultural University. The experimental

research was based on the results of treating 60 rabbits with deep III B degree burn wounds. All animals were chosen by the principle of analogs, the experiment involved rabbits of the gray giant breed weighing $4,535.00 \pm 49.30$ g at the age of 10 months. The animals were kept in individual cages, with free access to food and water. All animals had been quarantined for 14 days.

The planar burn wounds on the rabbits were made under overall anesthesia (Zoletil at the dosage of 5 mg/100 g) by applying a contact burn on the pre-shaved skin surface on the back. On day 5, tangential excision of burn eschar was made. All rabbits were divided into four groups. The reference group (n = 15) included the rabbits without treatment, i.e., with self-healing wounds. The wounded surfaces of the rabbits in experimental group I were treated two times a day with Panthenol spray, followed by the imposition of gauze bandages. The rabbits in experimental group II (n = 15) were treated with the Branolind N salve dressing (made in Germany) fixed with gauze cut out to the shape of the wounded area, and replaced daily. The rabbits in experimental group III (n = 15) were treated with the Derma RM wound dressing (based on bacterial cellulose). The DermaRM dressing was cut out in the operating room by a plastic template, repeating the contour of the wound, and used once. The efficiency of healing burn wounds was assessed by the speed of healing, the gross appearance of the wounds on days 5, 7, 14, 21, 28, and on the day of complete healing, and by the time of complete epithelialization of the burn surface. The speed of healing was assessed by the planimetric method (Mironov, et al., 2012). The area of the surface defect (S) was determined by the formula of F. Y. Boshinova with the use of plastic film and graph paper.

$S = (n+1/2 K) \times C$, where n is the number of filled 2×2 mm² cells; k is the number of unfilled 2×2 mm² cells; and s is the area of a single 2×2 mm² cell.

To calculate the area of the body surface (S b.s.) of the rabbits, the Meeh formula was used.

$S \text{ b.s.} = K \times W^{0.66}$, where K is the coefficient equal to 9.75 for rabbits (Chernigova, Chernigov, 2016a), W is the weight of the animal in grams.

The speed of burn wound epithelialization (ΔS) and reduction of the wound area was determined by the formula of L. N. Popova.

$\Delta S = ((S_n - S_{(n+1)}) / S_t) \times 100 \%$, where S_n is the area during the first measurement, mm²; S_{n+1} is the area during consequent measurements, mm²; and S_t is the number of days between measurements.

Statistical analysis of the results was performed using the Statistica 10 and Microsoft Excel 2010 software. The calculations were made using the methods of parametric statistics; with that, the arithmetic mean and the standard error of mean values were calculated. To determine the veracity of the differences, the Student's t-test and Fisher-Snedecor test were used.

Results and discussion

In the first days after the burn injury, the following clinical symptoms were noted in all animals in the reference and experimental groups: lethargy, unliveliness, refusal to eat, and excessive thirst. In the area of the burn wound,

the necrotic tissues of the skin fit tight to the underlying tissues, somewhat towering over the healthy tissues. On day 2 after modeling a burn, swelling and redness of the wound edges were observed in the rabbits; on the damaged part of the skin, pronounced coagulative necrosis was noted with the formation of an unevenly thick eschar. On days 3 – 4, the thick brown eschar towered over the healthy tissues, a clear demarcation line was formed that separated the eschar. On day 5, tangential excision of necrotic tissues was made in the surgery room.

In the rabbits in the reference group, the area of burn wounds was determined on the 7th day after necrectomy, which amounted to 2.4 % of the rabbit body surface (Table 1). In all animals in the reference group, local inflammatory processes were noted, accompanied by accumulation of the purulent-hemorrhagic exudate under the "secondary eschar".

Table 1. Planimetric indicators of healing dynamics of burn wounds in the animals, $M \pm m$

Groups of animals	The body surface area, cm ²	The burn wound area, mm ² (days after the burn wound surgical necrectomy)				
		1	7	14	21	28
Reference group, n = 15	2,444.3 ± 39.9	664.9 ± 10.0	586.8 ± 10.7	254.3 ± 11.8	189.8 ± 8.8	144.5 ± 6.4
Experimental group I, n = 15	2,544.2 ± 27.9	658.8 ± 9.8	441.7 ± 9.5*	333.7 ± 9.5*	197.7 ± 9.5	118.9 ± 7.1*
Experimental group II, n = 15	2,547.1 ± 37.3	712 ± 10.6*&	661.1 ± 23.5*&	316.1 ± 12.6*	282.8 ± 11.6*&	222.2 ± 13.7*&
Experimental group III, n = 15	2,557.1 ± 34.1	792.3 ± 18.1*& α	371.6 ± 13.6*& α	239.8 ± 12.1&	154.7 ± 10.2*& α	71.7 ± 7.5*& α

Note:
 * $p \leq 0.05$ – the veracity of the differences, compared to the reference group;
 & $p \leq 0.05$ – the veracity of the differences, compared to experimental group I;
 α $p \leq 0.05$ – the veracity of the differences, compared to experimental group II.

Further monitoring of the damaged area reparation showed that the area of the wound to the surface of the body ratio on day 14 was 1.04 %, on day 21 – 0.7 %, and on day 28 – 0.59 %. The diagram of the wound defect healing speed in the reference group was uneven, the most significant increase was noted in the period between 7 and 14 days. The peripheral wound epithelium in the rabbits in the reference group was noted only on day 16.7 ± 0.5 . Complete healing of the burn area in the rabbits in the

reference group occurred on day 51.7 ± 0.6 with the formation of dense scar tissue. By day 28, the total area of the wound had decreased by 2.13 % of the initial value.

In the rabbits in experimental group I, earlier completion of the inflammatory process and significant intensification of the peripheral epithelialization processes were noted, compared to the reference group. In the rabbits in experimental group I at the early stages of

observation, bandage fixation to the wound was noted; daily removal of the bandage was accompanied by capillary bleeding and epithelium trauma. As one can see from Table 1, in experimental group I, the area of the wound defect on the seventh day after necrotomy was 1.7 % of the body surface, on the fourteenth day – 1.3 %, and on the 21st day – 0.7 %. By day 28, the total area of the wound had decreased by 2.04 % of the initial value. The first symptoms of

epithelium appearance on the periphery of the wound in the rabbits in experimental group I were observed on average on day 9.1 ± 0.4 ($p \leq 0.05$), which was 7.6 days faster than in the reference group (Table 2). Complete healing of the wound was observed on day 43.4 ± 1.3 . An increased epithelialization speed had been noted up to seven days, after which a decreased intensity of the wound healing process was noted.

Table 2. Changes in the burn wounds healing rate in the animals according to the clinical characteristics, $M \pm m$

Groups of animals	Removing the "secondary" eschar from the wound, days	Appearance of peripheral epithelization,	Wound filling with the granulation tissue,
		days after necrectomy	
Reference group, n = 15	21.5 ± 0.5	16.7 ± 0.5	51.7 ± 0.6
Experimental group I, n = 15	$13.7 \pm 0.8^*$	$9.1 \pm 0.4^*$	$43.4 \pm 1.3^*$
Experimental group II, n = 15	$21.8 \pm 0.8\&$	$13.2 \pm 0.6^*\&$	$54.8 \pm 0.8^*\&$
Experimental group III, n = 15	$22.8 \pm 0.7\&$	$5.8 \pm 0.3^*\&\alpha$	$36.2 \pm 0.7^*\&\alpha$

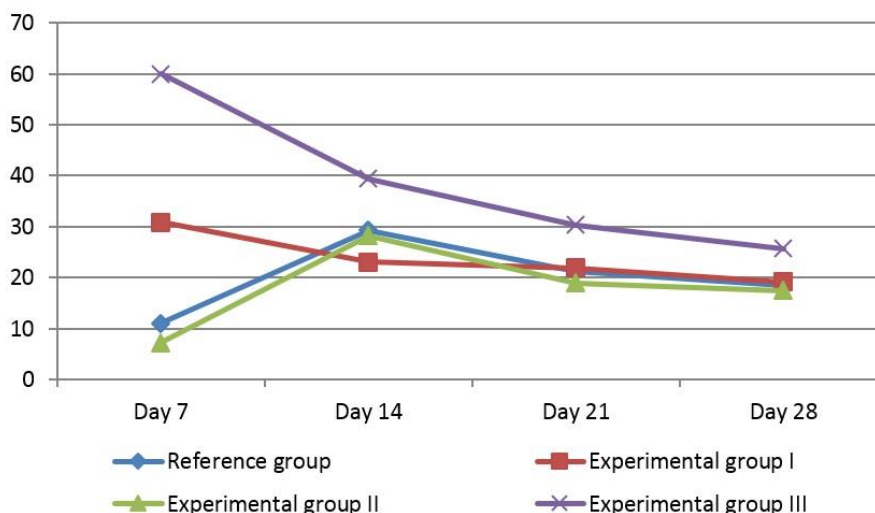
Note:
 * $p \leq 0.05$ – the veracity of the differences, compared to the reference group;
 & $p \leq 0.05$ – the veracity of the differences, compared to experimental group I;
 $\alpha p \leq 0.05$ – the veracity of the differences, compared to experimental group II.

Local application of the Branolind N dressing for the rabbits in experimental group II prevents trauma to the newly formed epithelium by the ointment base. However, it does not protect against mechanical and infectious exposure. Despite daily bandaging, the presence of purulent exudate for up to 35 days of the experiment was noted in the rabbits in experimental group II. Burn wounds healing in the rabbits in experimental group II, in general, was slow, and in most cases (53.3 %), complete healing was not achieved even on day 35. The wound area to the body surface percentage ratio in case of using the Branolind N salve dressing in experimental group II on day 7 reached 2.59 %, on day 14 –

1.2 %, and on day 21 – 1.1 %. By day 28, the total area of the wound had decreased by 1.92 % of the initial value.

An increased healing speed of burn wounds in the animals in experimental group II was noted in the period between 7 and 14 days. Complete epithelialization of the burn area in most rabbits in experimental group II did not occur, which was associated with the development of a secondary inflammatory process of infectious nature. On average, complete healing of wounds in the animals in this group was noted only on day 54.8 ± 0.8 (Figure 1).

Figure 1. The dynamics of burn wounds healing in the reference and experimental groups in various periods of observation, $M \pm m$



In experimental group III, a favorable clinical picture was noted. For instance, the overall state of the rabbits in this group was satisfactory as early as day two after the treatment. Rabbits readily consumed feed and water, the locomotor activity was preserved. After applying the Derma RM dressing on the surface of the burn wound, it was found that the dressing featured high elasticity, adapted to uneven surface, and ensured uniform compression of the tissues. In the animals in this group, the final hemostasis was achieved 1.8 ± 0.86 hours after the wound dressing was applied, secondary bleeding was not observed in the post-surgery period. During the macroscopic assessment of the changes in the burn surface with the use of the Derma RM wound dressing, earlier completion of the inflammatory process was noted, compared to the animals in other studied groups. The distinctive features of burn wounds healing in the rabbits in experimental group III were the presence of a slight swelling, the absence of hyperemia, and the absence of exudate under the necrotic layer as early as on day 2 – 3 of observation. It should be noted that the wound dressing was applied to the wound once, and not removed until complete epithelialization.

Statistical analysis of the planimetric study showed that the wound size reduction rate in experimental group III was significantly higher than that in the reference. Starting from day 3, the animals in experimental group III increased the wound healing rate, compared to other groups. Veracious reduction of the wound area was noted

as early as on day 7 after necrectomy (from 3.09 % to 1.45 %) ($p \leq 0.05$). On the next day, progressive healing of the injury was also noted, compared to the animals in the reference and experimental groups I and II. Morphometry of burn wounds in the rabbits in experimental group III showed that the beginning of epithelialization occurred as early as on day 5.8 ± 0.3 days ($p \leq 0.05$) of observation, whereas in the animals in the reference group, this happened only on day 16.7 ± 0.5 ($p \leq 0.05$) (Table 2). Healing of the burn wound occurred under the eschar; the peripheral epithelization 0.42 ± 0.1 cm wide was observed as early as on day 3 after necrectomy.

It should be noted that the results of the planimetric study showed that the healing process of burn wounds in the animals in experimental group III had been faster during the first seven days, which, in terms of time, corresponded to the first phase of wound healing – the inflammatory phase. Increase in the reparative processes is associated with the adequate removal of the exudative fluid and impeding the ingress of microorganisms onto the surface of the wound. In phases II and III wound epithelialization occurs under the wound dressing. The wound dressing based on bacterial cellulose is tightly attached to the burn surface, and remains there until complete regeneration of the damaged tissues; with that, rejection of the wound dressing was observed along the edge of the wound together with the peripheral formation of the granulation tissue. Full completion of burn wound regeneration through peripheral

epithelialization in the animals in experimental group III occurred on day 36.2 ± 0.7 , which was 15.5 days ($p \leq 0.05$) earlier than in the reference group, and 7.2 and 18.6 days ($p \leq 0.05$) earlier than in the rabbits in experimental groups I and II, respectively.

Conclusion

1. The use of wound dressing based on bacterial cellulose promotes rapid removing of necrotic masses from the burn wound, and has a positive effect on the epithelialization in phase I of the wound healing process, which results in reduced duration of treating animals with III B degree burns by 15.5 days ($p \leq 0.05$), compared to the reference group, and by 7.2 ($p \leq 0.05$) and 18.6 ($p \leq 0.05$) days, compared to experimental groups I and II, respectively.
2. Local use of the Derma RM wound dressing in the therapy of animals with burn wounds prevents inflammatory processes, and creates favorable conditions for the regeneration of damaged skin structures.
3. The use of the Derma RM wound dressing based on bacterial cellulose is recommended as a regenerative agent for treating III B degree deep burn wounds after surgical necrectomy, as well as at the stage of animal preparation for autodermoplasty.

References

- Abayev Y. K. (2006). Spravochnik khirurga. Rany i ranevaya infektsiya [Surgeon's reference book. Wounds and wound infection]. Rostov: Feniks.
- Chernigova S. V., Chernigov V. Y. (2016b). Dinamika metabolizma kollagena pri termicheskikh ozhogakh [Dynamics of collagen metabolism in thermal burns]. Proceedings of the international scientific-practical conference devoted to the Day of Russian Science Omsk «Actual problems of veterinary surgery». Omsk, 191-196.
- Chernigova S. V., Chernigov V. Y. (2016a). Dinamika perekisnogo okisleniya lipidov pri termicheskikh ozhogakh [Dynamics of lipid peroxidation in thermal burns] (experimental study). Proceedings of the I International Scientific-Practical Conference «Modern problems of fundamental and applied science development». Praha, 25-30.
- Chernigova S. V., Zubkova N. V., Chernigov Y. V., Pogorelova N. A. (2018). Doklinicheskoe issledovanie vliyaniya pokrytiya Dermarm na zazhivlenie ozhogovoy rany [Preclinical study of the effect of the Dermarm wound dressing on burn wound healing], Proceedings of the International Scientific-Practical Conference "Modern Problems of Radiobiology, Agroecology, Clinical and Experimental Veterinary Surgery", dedicated to the 90th anniversary of the birth of Academician A. D. Belov, the first President of the IAAE Saint-Petersburg, "Bulletin of the IAAE", 42(2), 204-210.
- Czaja W., Krystynowicz A., Bielecki S. (2006). Microbial cellulose – The natural power to heal wounds. *Biomaterials*, 27, 145-151.
- Kanjanamosit N., Muangnapoh C., Phisalaphong M. (2009). Biosynthesis and characterization of bacteria cellulose-alginate film. *J. Appl. Polym. Sci.*, 115, 1581-1588.
- Mironov A. N., et al. (2012). Rukovodstvo po provedeniyu doklinicheskikh issledovaniy lekarstvennykh sredstv [Guidelines for preclinical studies of pharmaceuticals]. Part one. Moscow: Grif and K.
- Nazarenok G. I., Sugorova I. Y., Glyantsev S. P. (2002). Rana. Povyazka. Bolnoy. Sovremennye meditsinskie tekhnologii [Wound. Bandage. Patient. Modern medical technologies]. Moscow: Medicine.
- Paramonov B. A., Poremsky Y. O., Jablonsky V. G. (2000). Ozhogi: Rukovodstvo dlya vrachey [Burns: A guide for physicians]. Saint Petersburg: SpetsLit.
- Popov V. A. (2013). Ranevoy protsess: nanobitenolgiy optimizatsii [Wound process: nano-biotechnologies of optimization]. Saint Petersburg: SpetsLit.
- Privolnev V. V., et al. (2016). Mestnoe lechenie ran i ranevoy infektsii po rezultatam anonimnogo anketirovaniya khirurgov Rossii. Rany i ranevye infektsii [Local treatment of wounds and wound infection according to the results of anonymous questioning of surgeons of Russia. Wounds and wound infection]. *Journal n.a. Prof. B. M. Kostyuchenok*, 3(1), 19-24.
- Schmidt-Nielsen K. (1987). Razmery zhivotnykh: pochemu oni tak vazhny? [Why is animal size so important?]. Moscow: Mir.
- Wang J., Wan Y., Han J., Lei X., Yan T., Gao C. (2011). Nanocomposite prepared by immobilising gelatin and hydroxyapatite on bacterial cellulose nanofibres, *Micro Nano Lett*, 6, 133-136.